

CASE REPORT

PEER REVIEWED | OPEN ACCESS

Opportune identification and surgical management of nonfunctional pancreatic neuroendocrine tumor: A case report

María C Reyes, Michelle Vanessa Peñaherrera Pazmiño, Ruth A Rojas, Edwin V Gualacata, Andrés Andrade, Diego M López

ABSTRACT

Introduction: Pancreatic neuroendocrine tumors are a heterogeneous group of epithelial neoplasms with variable clinical presentation and malignant potential. Nonfunctional tumors do not secrete hormones; therefore, they have a late presentation with symptoms that reflect local compression or metastasis. Besides, they could show an aggressive behavior with poor prognosis as proliferation outside pancreas. Hence, making a decision between surgical management and observational behavior has to be personalized for each patient.

Case Report: A 38-year-old female patient case is reported. She had a nonfunctional neuroendocrine tumor of 5 mm length. The patient was subjected to a laparoscopic distal pancreatectomy, and due to the findings during the procedure, it was decided to perform splenectomy.

Conclusion: According to literature, this type of tumors has low-frequency presentation. Furthermore,

it is confirmed that an opportune management has been performed by following the international guideline recommendations.

Keywords: Distal pancreatectomy, Nonfunctional pancreatic neuroendocrine tumors, Pancreatic neuroendocrine tumors

How to cite this article

Reyes MC, Pazmiño MVP, Rojas RA, Gualacata EV, Andrade A, López DM. Opportune identification and surgical management of nonfunctional pancreatic neuroendocrine tumor: A case report. J Case Rep Images Surg 2021;7:100089Z12MR2021.

Article ID: 100089Z12MR2021

doi: 10.5348/100089Z12MR2021CR

María C Reyes¹, Michelle Vanessa Peñaherrera Pazmiño², ORCID ID: <https://orcid.org/0000-0002-8535-5112>, Ruth A Rojas², ORCID ID: <https://orcid.org/0000-0003-4629-123X>, Edwin V Gualacata¹, Andrés Andrade², Diego M López²

Affiliations: ¹General Laparoscopic Specialist Surgeon, Hospital General Docente de Calderón, Quito, Ecuador; ²Postgraduate Medical Doctor, PGY4, UCE General Surgery, Hospital General Docente de Calderón, Quito, Ecuador.

Corresponding Author: Michelle Vanessa Peñaherrera Pazmiño, Valle de los Chillós, San Rafael, Mariana de Jesús 251, "Roble Antiguo" residency, House #16, Post code: 171101, Quito, Pichincha, Ecuador; Email: michu_vane@hotmail.com

Received: 03 November 2020

Accepted: 21 February 2020

Published: 26 March 2021

INTRODUCTION

There are tumors which proceed from pancreatic islet cells. These tumors are known as pancreatic neuroendocrine tumors (PNETs) [1]. PNETs represent a heterogeneous group of epithelial neoplasms; their clinical presentation, malignant potential, and prognosis are variables as well as their size features, growth, and functionality [2]. These tumors represent 1–2% of pancreatic tumors [1, 3], 4–8% of neuroendocrine tumors [2], and they have an increasing incidence from 1 to 6 per million [4].

These tumors are classified as nonfunctional tumors that correspond to 60% of the PNETs and functional tumors that produce hormones such as insulin, glucagon, somatostatin ghrelin, and pancreatic polypeptides [1,

5]. The majority of PNETs are solid; however, 10% present cystic characteristics which seem biologically less aggressive than solid ones [6]. Many PNETs are asymptomatic, they do not tend to metastasize, and they have a favorable prognosis in the long term, while other high-grade tumors with early metastasis progression are considered aggressive [7].

Life expectancy is high in people with localized disease amenable to surgery, which indicates the importance of diagnosis [8].

Approximately 5% of patients with PNETs have a related family history and 95% are sporadic. Among the related hereditary conditions are multiple endocrine neoplasms type 1 (MEN1), von Hippel–Lindau syndrome (VHL), tuberous sclerosis complex (TSC1 and TSC2), and neurofibromatosis (NF). These conditions are related to multifocal presentation tumors [1].

Surgical resection represents the cornerstone in the disease management and the approach type depends on PNETs' features and behaviors [7]. For localized PNETs, pancreaticoduodenectomy or distal pancreatectomy is the standard treatment, while enucleation and observation can be considered for small tumors [9]. The management of metastatic PNETs includes a multimodal management of primary resection, surgical reduction, directed therapy at liver metastases, and various systemic treatments [9].

CASE REPORT

A 38-year-old female patient, who neither reports personal pathological record nor family pathological medical history, presented abdominal pain located at the epigastrium with seven months evolution. In addition, laboratory results were within normal parameters. Furthermore, gastric, biliary, or pancreatic pathology were excluded; given the persistence of symptoms, it was decided to perform an abdominal tomography in which a cystic lesion of 8.6 mm was observed at pancreatic tail level and malignancy was not ruled out (Figure 1). Tumoral markers analysis were requested and negative results were obtained (CA 19-9: 5.32 U/mL, AFP: 2.12 ng/mL, CEA: 1.13 ng/mL). In view of this described lesion associated with the patient's symptomatology, and according to the guidelines, as described further, the team decided to perform a laparoscopic distal pancreatectomy. During the procedure, a nodular lesion larger than 1 cm was evidenced toward the edge of the pancreatic tail in relation to the spleen, so it was decided to perform a splenectomy, a procedure that took place without transoperative complications, in a surgical time of 3 hours (Figure 2). The patient remained hospitalized for seven days and she showed a favorable evolution. She presented a self-limited pancreatic fluid leak, classified as a biochemical leak according to the 2016 new classification of postoperative pancreatic fistulas [10].

Histopathology studies report an ill-defined nodular lesion of 5 mm (Figure 3) which is compatible with a well

differentiated multifocal neuroendocrine tumor, grade 2, Ki67: 3% with a mitotic rate of 7 mitosis per 2 mm². In the tail of the pancreas, there was unidentified lymphovascular and perineural invasion, with stage PT1PNO PMO. There were additional pathological findings of adenomatosis and splenic congestion, chromogranin and synaptophysin positive immunoreactivity (Figure 4), and somatostatin, gastrin, and insulin negative immunoreactivity (Figure 5).

The patient presented a final diagnosis of well differentiated multifocal nonfunctional neuroendocrine tumor in the tail of the pancreas PT1PNO PMO, was followed up for two years during which new tomographic studies were performed with no evidence of recurrence of the disease, the patient did not receive chemotherapy.

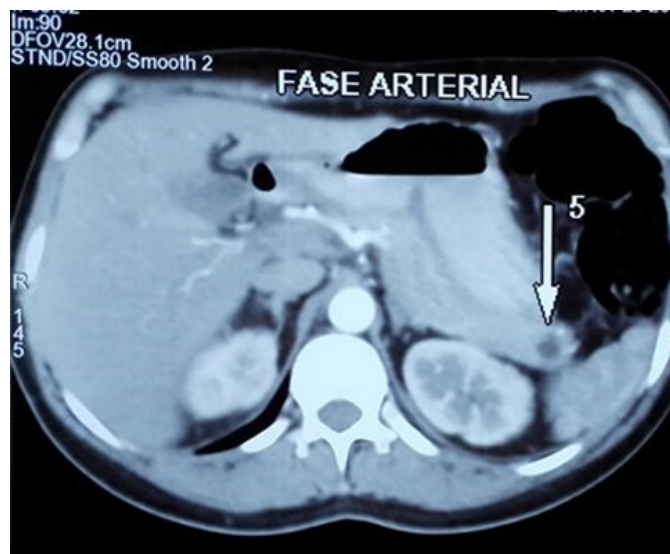


Figure 1: 8.6 mm cystic lesion at the level of the pancreatic tail, cystic mucinous neoplasm is not ruled out.

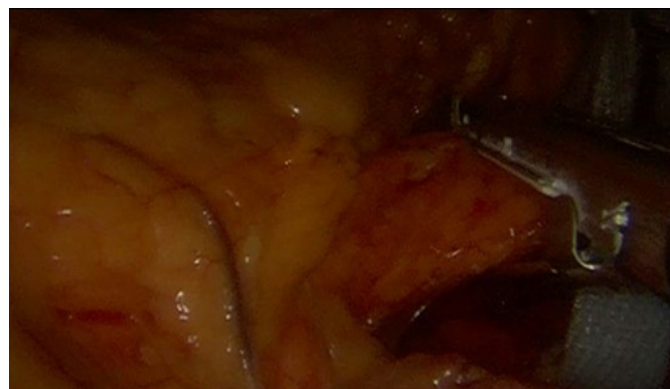


Figure 2: Laparoscopic image of pancreatic tail section with auto-suture.

DISCUSSION

Pancreatic neuroendocrine tumors are neoplasms that show varied development and prognosis. Their incidence is 0.43 per 100,000 and they represent 1–2% of all pancreatic neoplasms [3, 11]. They are considered relatively

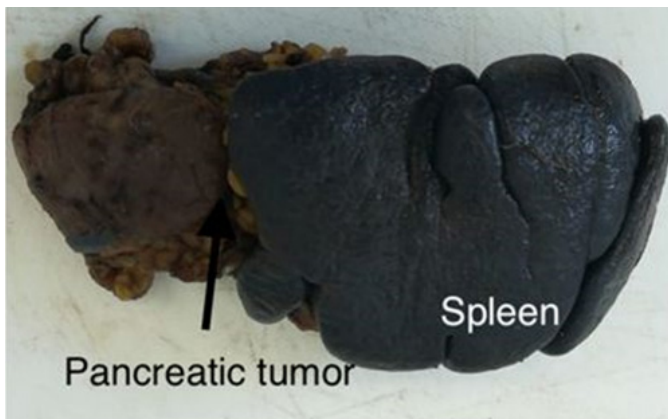


Figure 3: Surgical specimen with evidence of tumor adhered to the spleen.

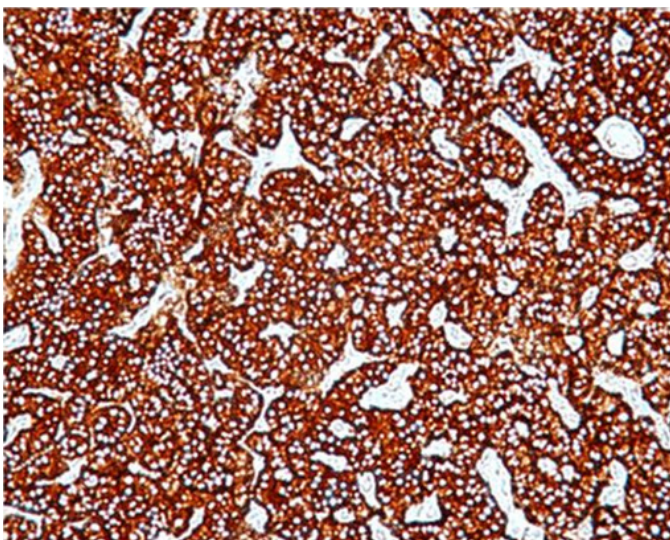


Figure 4: Well differentiated neuroendocrine tumor with synaptophysin positive immunoreactivity.

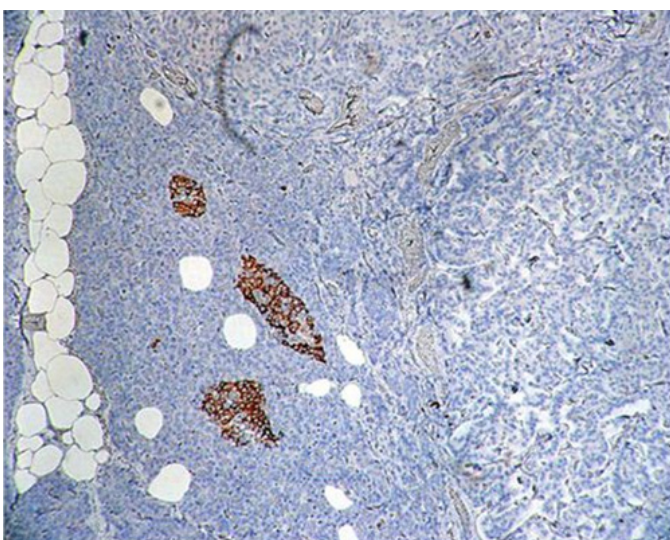


Figure 5: Well differentiated neuroendocrine tumor with insulin negative immunoreactivity.

rare, approximately 1000 new cases in United States yearly. Pancreatic neuroendocrine tumors constitute 7% of the neuroendocrine gastroenteropancreatic neoplasms [12]. They can vary from benign lesions to low-grade-malignant and less frequent, to high grade lesions or metastatic lesions [3].

Recent studies describe that incidentally detectable and resectable lesions, even smaller than 2 cm, can develop recurrence and metastasis in 7–15% of cases [13].

Nonfunctional neuroendocrine tumors (NF-PNETs) do not secrete hormones such as insulin, gastrin, or somatostatin; however, they produce other peptides like chromogranin A, neuron-specific enolase, and synaptophysin which are serological and histological markers used for diagnosis and surveillance of these tumors [7, 12].

Pancreatic neuroendocrine tumors diagnosis used to be performed when hormonal symptoms were present, it means due to functional tumors. In contrasts, most tumors are currently diagnosed as nonfunctional incidentally [14]. Nonfunctional tumors do not secrete hormones therefore they have a late presentation when symptoms reflect local compression or metastasis. Literature describes asymptomatic presentation or with abdominal pain (35–78%), like in the presented case. Furthermore, they can show weight loss (20–35%), anorexia, and nausea (45%) [12]. This could be ascribed to incidental findings in tomographies indicated to other pathologies [15].

Once NF-PNETs have been identified, pathological confirmation is vital because they can present aggressive behavior with a poor prognosis such as outside pancreatic extension, lymphatic nodule metastasis, distant metastasis, or recurrence [11]. Hence, Yang et al. in a consensus published in 2017 in China on the management of PNETs-NF recommended PNETs-NF < 2 cm should undergo tumor resection except for selected patients with PNETs-NF < 1 cm, evidenced incidentally and with an unacceptable surgical risk [11].

Literature recommends that the decision between surgical management and observation of NF-PNETs has to be personalized according to patient's comorbidities, tumor growth, symptomatology, access to follow-up, and others [1].

When a nonfunctional pancreatic tumor is found, the National Comprehensive Cancer Network (NCCN) recommends performing biochemical studies. Therefore, in our case we have followed the recommendations with our patient including the analysis of tumoral markers and a negative result was obtained. It is catalogued as locoregional small lesion as it measures less than 2 cm and NCCN considers the surgical management with distal pancreatectomy with or without splenectomy as one the management options [16].

As it was a symptomatic mass, surgical resolution was decided by laparoscopic distal pancreatectomy and splenectomy is performed due to the aforementioned transsurgical findings, without transoperative

complications. After surgery, the patient developed a self-limited Clavien–Dindo grade 1 complication, a post-surgical pancreatic fistula, which represents one of the most common complications after a pancreatic surgery. Nevertheless, due to its clinical feature, according to the new classification and pancreatic fistula definition in 2016, it corresponds to a biochemical leaking due to a duration of less than 21 days [10].

World Health Organization (WHO) classified tumors in neuroendocrine grade 1 (G1), grade 2 (G2), and neuroendocrine carcinoma as grade 3 (G3) in 2010. This classification takes into account Ki-67 nuclear protein, which is expressed in active phases of cell cycle, and the mitosis number per 10 high-power fields (HPFs) [3]. Neuroendocrine G1 tumors have a mitosis number lower than 2 per 10 HPFs (high-power fields) and Ki-67% less or equal to 2%, NET G2 tumors have a lower mitosis number which is between 2 and 20 per 10 HPFs and Ki-67% from 3% to 20% and it has a five-year survival of 22%, whereas NET G3 tumors present a mitosis number higher than 20 per 10 HPFs and Ki-67% higher than 20% and they have a five-year survival of 61% [3, 13]. In this case report, the patient presents a NET G2 at PT1 PNO PMO histopathological reported stage.

Immunohistochemical studies revealed positive immunoreactivity to chromogranin and synaptophysin, negative immunoreactivity to somatostatin, insulin and gastrin which are in agreement to the expected NF-PNETs behavior reported by literature.

Our motivation to present this case bases on the fact that pancreatic neuroendocrine tumor presentation is unusual. In this case report, the managed algorithm suggested by NCCN is fulfilled and a favorable patient's evolution after surgical resolution due to symptomatology presentation is shown. During 2-year monitoring, tomographies or adenomegalies have not presented relapse.

CONCLUSION

The pancreatic neuroendocrine tumor diagnosed in our patient is nonfunctional and sporadic. Although the literature catalogs these tumors as indolent, the timely diagnosis is made by the symptomatology of abdominal pain despite the size of the lesion. Our patient was treated by surgical excision of the lesion, where its location near the splenic hilum required splenectomy, her management to date has been classified as curative treatment due to the absence of evidence of recurrence during her follow-up.

REFERENCES

1. Howe JR, Merchant NB, Conrad C, et al. The North American Neuroendocrine Tumor Society consensus paper on the surgical management of pancreatic neuroendocrine tumors. *Pancreas* 2020;49(1):1–33.

2. Mukherjee JJ, Lee KO, Kaltsas G. Section 8 neoplastic tumors of the endocrine pancreas: Neuroendocrine tumors of the pancreas epidemiology and classification of neuroendocrine tumors of the pancreas introduction epidemiology of pancreatic. In: Beger HG, Warshaw AL, Hruban RH, et al. editors. *The Pancreas: An Integrated Textbook of Basic Science, Medicine, and Surgery*. 3ed. Hoboken, NJ: John Wiley & Sons Ltd.; 2018. p. 919–29.
3. Gorelik M, Ahmad M, Grossman D, Grossman M, Cooperman AM. Nonfunctioning incidental pancreatic neuroendocrine tumors: Who, when, and how to treat? *Surg Clin North Am* 2018;98(1):157–67.
4. Ladner DP, Norton JA. Chapter 97 - Neuroendocrine tumors of the pancreas. In: *Shackelford's Surgery of the Alimentary Tract, 2 Volume Set*. 8ed. Elsevier Inc.; 2019. p. 1149–57.
5. Öberg K. Management of functional neuroendocrine tumors of the pancreas. *Gland Surg* 2018;7(1):20–7.
6. Cloyd JM, Kopecky KE, Norton JA, et al. Neuroendocrine tumors of the pancreas: Degree of cystic component predicts prognosis. *Surgery* 2016;160(3):708–13.
7. Liu JB, Baker MS. Surgical management of pancreatic neuroendocrine tumors. *Surg Clin North Am* 2016;96(6):1447–68.
8. Brooks JC, Shavelle RM, Vavra-Musser KN. Life expectancy in pancreatic neuroendocrine cancer. *Clin Res Hepatol Gastroenterol* 2019;43(1):88–97.
9. Scott AT, Howe JR. Evaluation and management of neuroendocrine tumors of the pancreas. *Surg Clin North Am* 2019;99(4):793–814.
10. van Hilst J, de Pastena M, de Rooij T, et al. Clinical impact of the updated international postoperative pancreatic fistula definition in distal pancreatectomy. *HPB (Oxford)* 2018;20(11):1044–50.
11. Yang G, Ji M, Chen J, et al. Surgery management for sporadic small (≤ 2 cm), non-functioning pancreatic neuroendocrine tumors: A consensus statement by the Chinese Study Group for Neuroendocrine Tumors (CSNET). *Int J Oncol* 2017;50(2):567–74.
12. Laird AM, Libutti SK. Chapter 20 - Advances in the diagnosis and management of nonfunctional pancreatic neuroendocrine tumors. In: *Advances in Treatment and Management in Surgical Endocrinology*. Elsevier; 2020. p. 221–32.
13. Reid MD, Balci S, Saka B, Adsay NV. Neuroendocrine tumors of the pancreas: Current concepts and controversies. *Endocr Pathol* 2014;25(1):65–79.
14. Zerbi A, Falconi M, Rindi G, et al. Clinicopathological features of pancreatic endocrine tumors: A prospective multicenter study in Italy of 297 sporadic cases. *Am J Gastroenterol* 2010;105(6):1421–9.
15. Cheema A, Weber J, Strosberg JR. Incidental detection of pancreatic neuroendocrine tumors: An analysis of incidence and outcomes. *Ann Surg Oncol* 2012;19(9):2932–6.
16. Lurie RH, Cancer C. Neuroendocrine and Adrenal Tumors - NCCN Guideline. 2020. p.1–41. [Available at: https://www.nccn.org/professionals/physician_gls/pdf/neuroendocrine.pdf]

Acknowledgments

Special thanks to Hospital General Docente de Calderón, where the patient was received, diagnosed, undergone surgical treatment, and followed up of her pathology.

Author Contributions

María C Reyes – Conception of the work, Design of the work, Acquisition of data, Analysis of data, Interpretation of data, Drafting the work, Revising the work critically for important intellectual content, Final approval of the version to be published, Agree to be accountable for all aspects of the work in ensuring that questions related to the accuracy or integrity of any part of the work are appropriately investigated and resolved

Michelle Vanessa Peñaherrera Pazmiño – Conception of the work, Design of the work, Acquisition of data, Analysis of data, Interpretation of data, Drafting the work, Revising the work critically for important intellectual content, Final approval of the version to be published, Agree to be accountable for all aspects of the work in ensuring that questions related to the accuracy or integrity of any part of the work are appropriately investigated and resolved

Ruth A Rojas – Conception of the work, Drafting the work, Revising the work critically for important intellectual content, Final approval of the version to be published, Agree to be accountable for all aspects of the work in ensuring that questions related to the accuracy or integrity of any part of the work are appropriately investigated and resolved

Edwin V Gualacata – Interpretation of data, Drafting the work, Revising the work critically for important intellectual content, Final approval of the version to be published, Agree to be accountable for all aspects of the work in ensuring that questions related to the accuracy or integrity of any part of the work are appropriately investigated and resolved

Andrés Andrade – Interpretation of data, Drafting the work, Revising the work critically for important

intellectual content, Final approval of the version to be published, Agree to be accountable for all aspects of the work in ensuring that questions related to the accuracy or integrity of any part of the work are appropriately investigated and resolved

Diego M López – Acquisition of data, Drafting the work, Revising the work critically for important intellectual content, Final approval of the version to be published, Agree to be accountable for all aspects of the work in ensuring that questions related to the accuracy or integrity of any part of the work are appropriately investigated and resolved

Guarantor of Submission

The corresponding author is the guarantor of submission.

Source of Support

None.

Consent Statement

Written informed consent was obtained from the patient for publication of this article.

Conflict of Interest

Authors declare no conflict of interest.

Data Availability

All relevant data are within the paper and its Supporting Information files.

Copyright


© 2021 María C Reyes et al. This article is distributed under the terms of Creative Commons Attribution License which permits unrestricted use, distribution and reproduction in any medium provided the original author(s) and original publisher are properly credited. Please see the copyright policy on the journal website for more information.

Access full text article on other devices



Access PDF of article on other devices





INTERNATIONAL JOURNAL OF CASE REPORTS AND IMAGES



VIDEO JOURNAL OF CLINICAL RESEARCH



VIDEO JOURNAL OF BIOMEDICAL SCIENCE



INTERNATIONAL JOURNAL OF HEPATOBILIARY AND PANCREATIC DISEASES




INTERNATIONAL JOURNAL OF BLOOD TRANSFUSION AND IMMUNOHEMATOLOGY



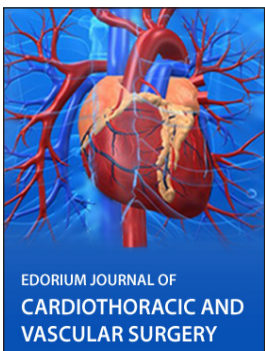EDORIUM JOURNAL OF OPHTHALMOLOGY



Submit your manuscripts at
www.edoriumjournals.com



EDORIUM JOURNAL OF MEDICINE



EDORIUM JOURNAL OF CARDIOTHORACIC AND VASCULAR SURGERY



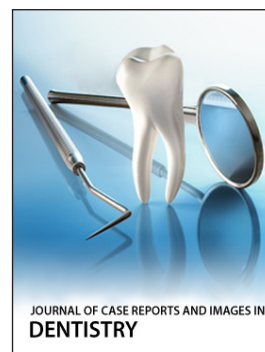JOURNAL OF CASE REPORTS AND IMAGES IN ORTHOPEDICS AND RHEUMATOLOGY



EDORIUM JOURNAL OF PSYCHOLOGY



EDORIUM JOURNAL OF CELL BIOLOGY



JOURNAL OF CASE REPORTS AND IMAGES IN DENTISTRY



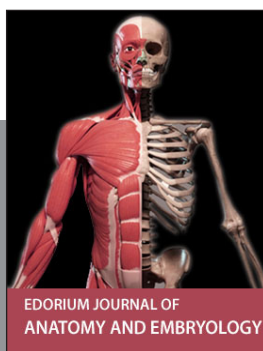EDORIUM JOURNAL OF CANCER



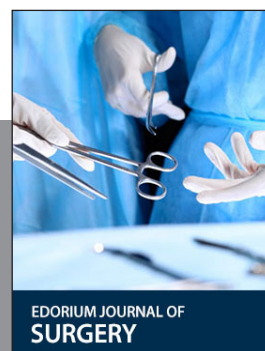
EDORIUM JOURNAL OF PSYCHIATRY



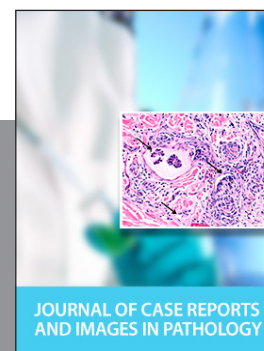JOURNAL OF CASE REPORTS AND IMAGES IN INFECTIOUS DISEASES



EDORIUM JOURNAL OF ANATOMY AND EMBRYOLOGY



EDORIUM JOURNAL OF SURGERY



JOURNAL OF CASE REPORTS AND IMAGES IN PATHOLOGY



EDORIUM JOURNAL OF ANESTHESIA